

Key Anatomical Features & Landmarks in the oral Cavity:

F

P

D

ANATOMY OF PERIODONTIUM:

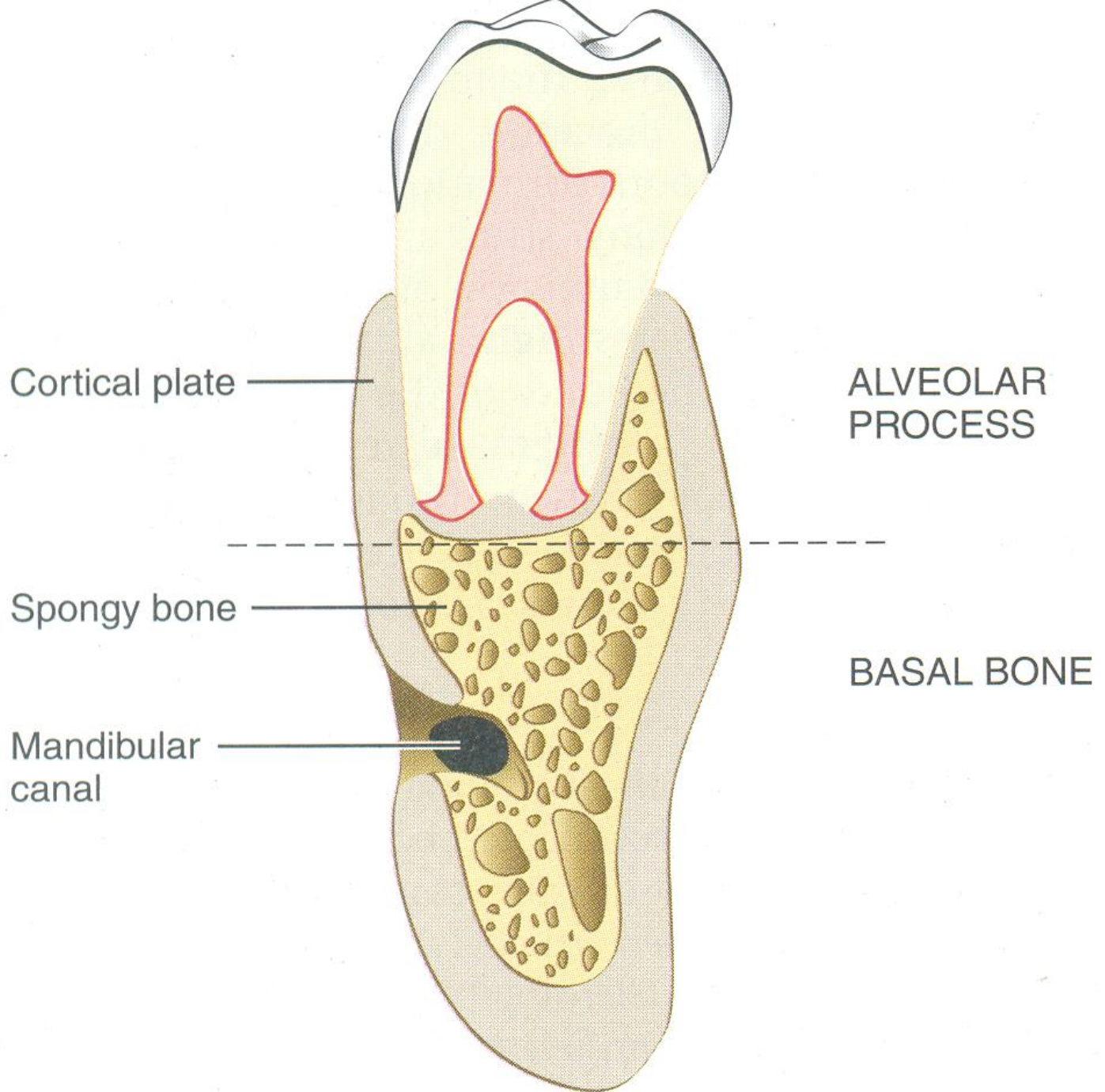
Comprises of Gingiva,
PDL, Alveolar bone &
Root Cementum

ALVEOLAR BONE

Alveolar bone

- The bony portion of the mandible or the maxillae in which the roots of the teeth are held by the fibres of the periodontal ligament, also called as dental alveolus

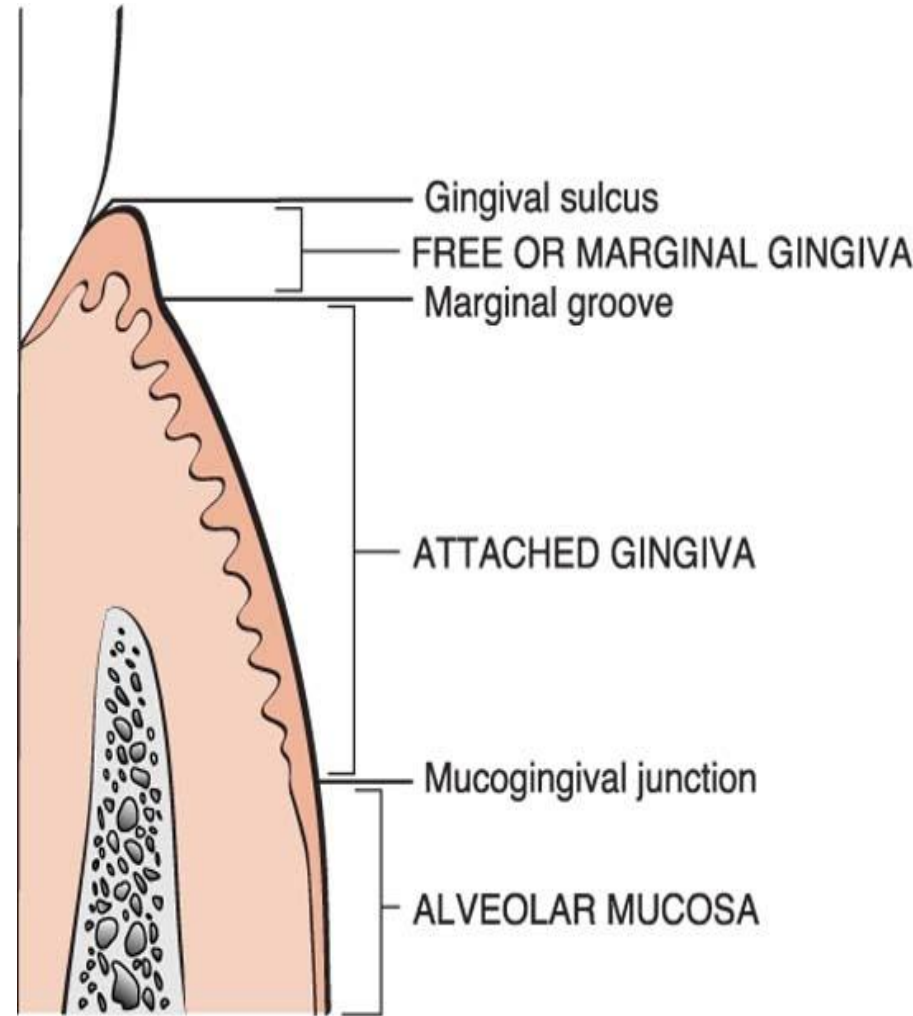
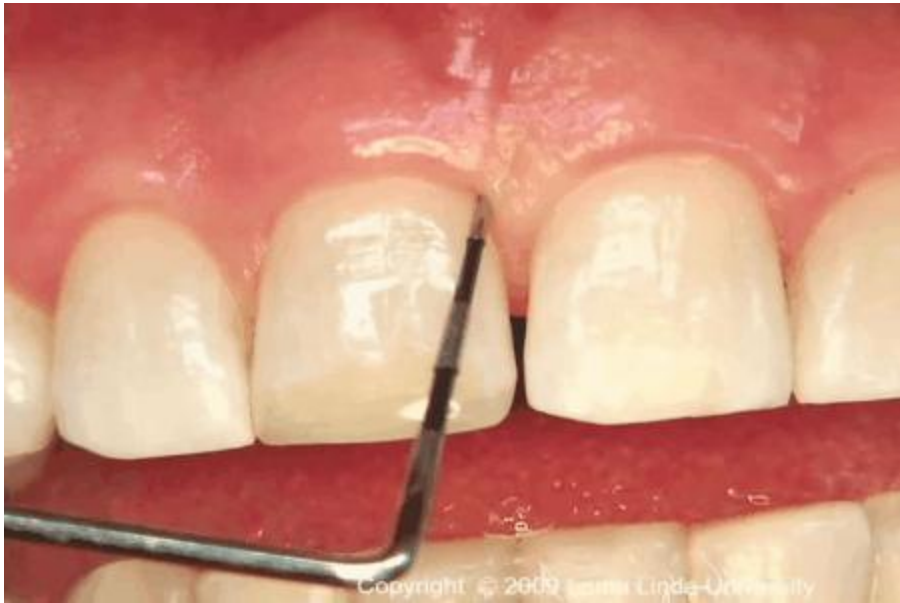GPT 9.



GINGIVA

- **Definitions**

- The gingiva or gums, consists of the mucosal & connective tissue that lays over the jawbone*



Copyright © 2002, W.B. Saunders Company

Biological width

- Biological width is the natural distance between the base of the gingival sulcus and the height of the alveolar bone. The gingival sulcus is a little crevice that lies between the enamel of the tooth crown and the sulcular epithelium.
- **Mean values**
 - functional epithelium- 0.97mm
 - connective tissue attachment- 1.07mm
 - biological width = 0.97mm+1.07mm
 - =2.04mm

Schematic figure: BW

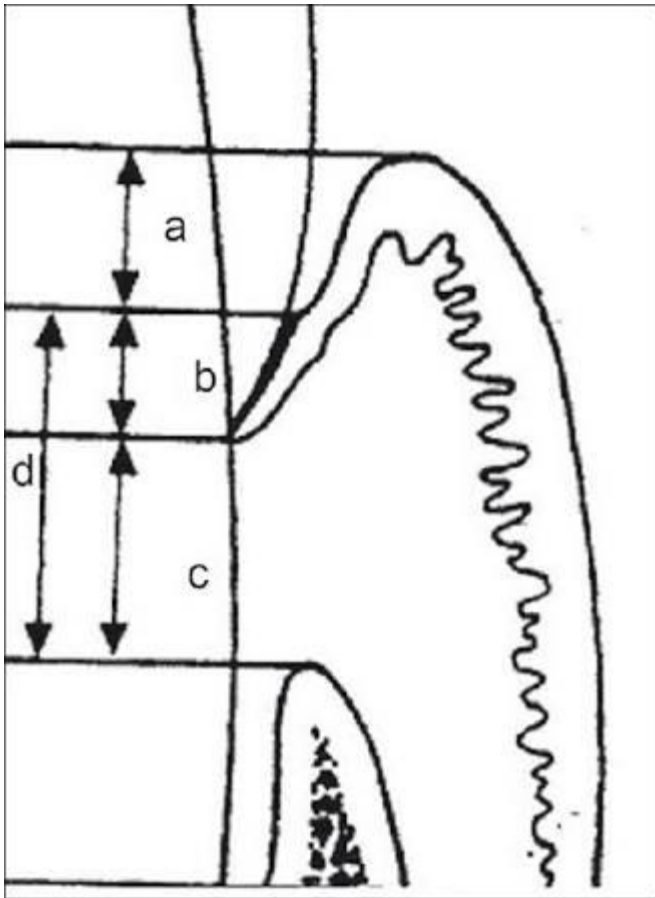
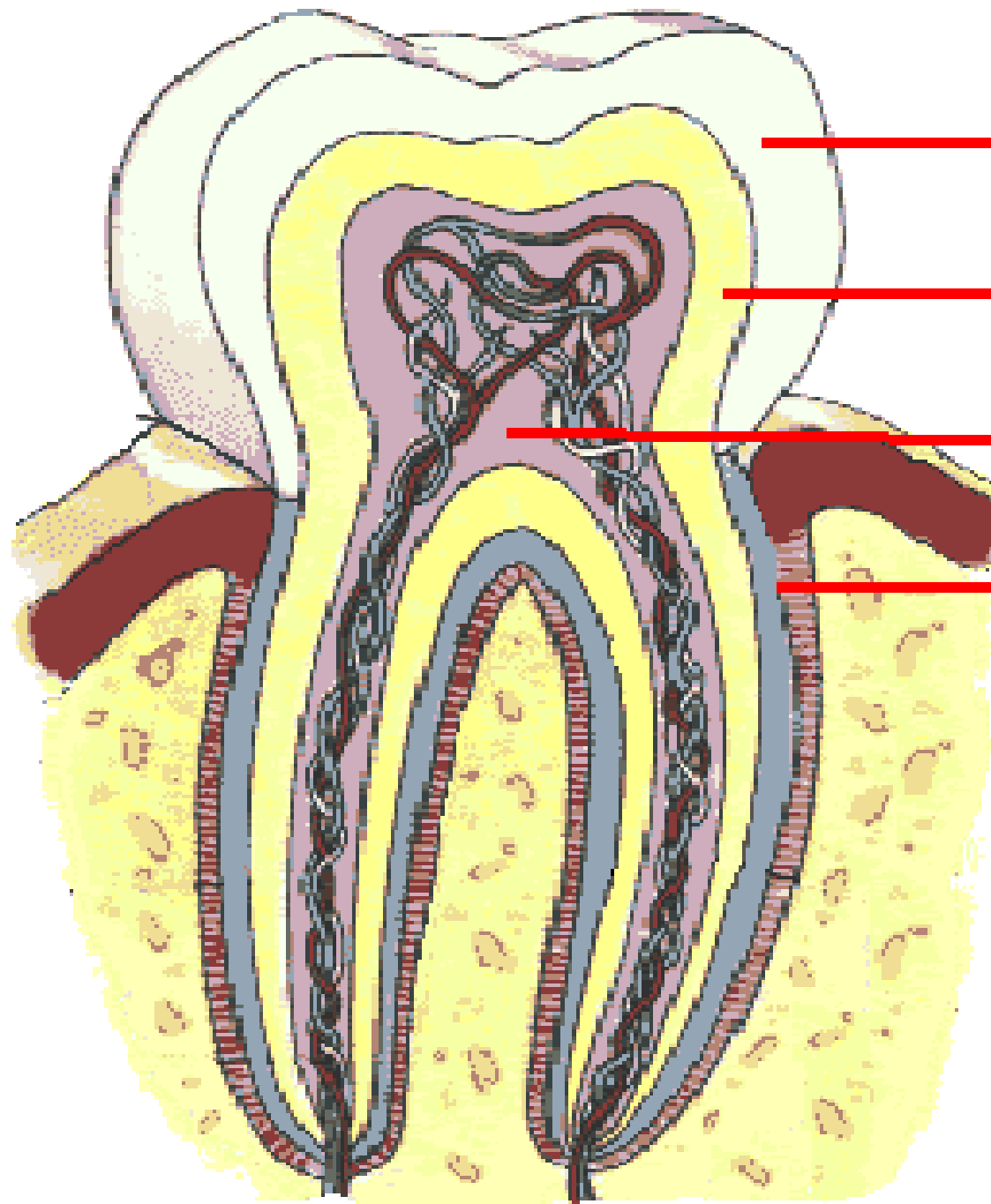


Figure 1: (a) Histological sulcus (0.69 mm), (b) Epithelial attachment (0.97 mm), (c) Connective tissue attachment (1.07 mm), (d) Biologic width (b+c)

- The **biologic width** can be identified by probing under local anesthesia to the bone level (referred to as "sounding to bone") and subtracting the sulcus depth from the resulting **measurement**.

CEMENTUM

- Cementum is the calcified mesenchymal tissue that forms the outer covering of the anatomical root “Caranza Newman 8th edition”.



Enamel

Dentin

Pulp

Cementum

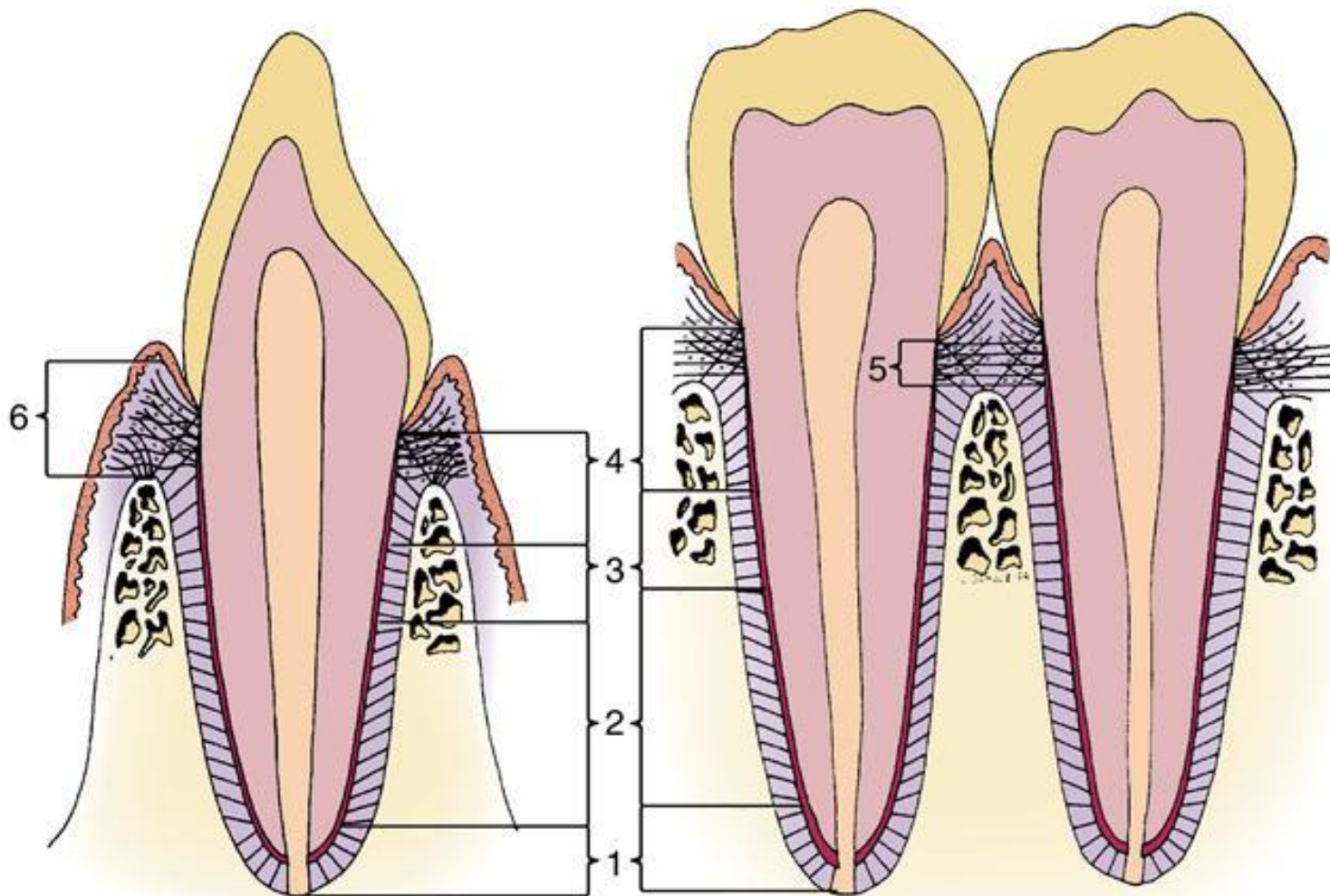
PERIODONTAL LIGAMENT:

It's the connective tissue that surrounds the root and connects it to the bone. Its mainly made of soft tissue and collagen fibers as attachment complex –

- I. Junctional epithelium
- II. Supracrestal fibres

Buccolingual

Mesiodistal



1. Apical
2. Oblique
3. Horizontal
4. Alveolar crest
5. Transseptal
6. Gingival group